

Original Article

Treatment for delayed and chronic fracture dislocation of the shoulder

Chung-Hsun Chang^a, Kuo-Yao Hsu^b, Alvin Chao-Yu Chen^{b,*}^a Department of Orthopaedic Surgery, Taipei Medical University, Wan Fang Hospital, Taipei, Taiwan^b Department of Orthopaedic Surgery, Chang Gung Memorial Hospital, Taoyuan, Taiwan

A B S T R A C T

Keywords:
chronicity
fracture dislocation
humerus
shoulder

Background: Chronic fracture dislocation of the shoulder is really rare clinically. In the literature, treatment of these cases was barely discussed. Here, we review the results of this kind of cases treated at our hospital. **Methods:** Nine patients with delayed or chronic fracture dislocation of the shoulder were treated at our hospital from February 2000 to April 2007. Three of them who received shoulder hemiarthroplasty were excluded from this study. The other six patients received procedures of open reduction and internal fixation with buttress plate and allografting at the fracture site. The average age of the six patients at the index surgery was 46.2 years. The average time between injury and treatment was 40 days. The average follow-up period was 10.4 months.

Results: Four patients with missed diagnosis and who received first time surgery had no pain over the involved shoulder and no limitation in the daily activities. They were all satisfied with the results. However, two patients with failed previous surgery got nonunion of the fracture site after the revision surgery.

Conclusions: For patients with misdiagnosed fracture dislocation of the shoulder, open reduction, internal fixation, and allografting can be performed if the articular cartilage is intact and a satisfactory result can be expected. However, for revision surgery, resorption of the fracture site may develop even with allografting and rigid fixation. Shoulder hemiarthroplasty is therefore a better treatment for these patients.

Copyright © 2011, Taiwan Orthopaedic Association. Published by Elsevier Taiwan LLC. All rights reserved.

1. Introduction

Fractures of the proximal humerus are the second most common fractures of the upper extremity and account for about 4%–5% of all fractures.¹ Most proximal humeral fractures are minimally displaced and can be treated conservatively. The fractures are markedly displaced in only about 20% of the cases and require surgical intervention.² A well-accepted classification system proposed by Neer for proximal humeral fractures is used to guide the treatment regimen.³

On the basis of the findings reported by Neer, shoulder hemiarthroplasty is indicated for comminuted fractures, such as a three-part fracture of an osteoporotic bone, four-part fracture, or fracture dislocation of the shoulder because of the difficulty in fixation of fracture fragments of an osteoporotic bone and high rate of osteonecrosis of the humeral head after healing of these fractures. However, the prognosis of shoulder hemiarthroplasty is not very good. Although this treatment approach is effective for alleviating pain, the range of motion of the shoulder is less predictable.^{4–6}

Chronic fracture dislocation of the shoulder is extremely rare in daily practice and only two case reports have been published.^{7,8} For patients with low demands, shoulder hemiarthroplasty is the treatment of choice; but for young and active patients, open reduction and internal fixation may provide a better prognosis. Herein, we report our experience in treating patients with chronic fracture dislocation of the shoulder with open reduction and internal fixation.

2. Materials and methods

From February 2000 to April 2007, nine patients received treatment at our hospital for delayed or chronic fracture dislocation of the shoulder. Seven of the patients were male and two were female. Three male patients were excluded from this study because they underwent shoulder hemiarthroplasty because of destruction of the posteriorly dislocated humeral head.

The diagnosis of fracture dislocation of the shoulder was missed at first in four patients. The other two patients underwent revision operation for persistent dislocation of the humeral head after previous surgery. Three of the six cases were identified as being posteriorly dislocated. Among the misdiagnosed cases, two patients had a two-part fracture with anterior dislocation, whereas

* Corresponding author. Division of Sports Medicine, Department of Orthopaedic Surgery, Chang Gung Memorial Hospital, 5, Fu-Hsing St., Kweishan, Taoyuan, Taiwan. Tel.: +886 3 3281200x3882; fax: +886 3 3278113.

E-mail address: alvinchen@adm.cgmh.org.tw (A.C.-Y. Chen).

the other two patients had a three-part fracture with posterior dislocation. Between the two cases with revision surgery, the humeral head stayed dislocated anteriorly in one female and posteriorly in the other male after the first surgery.

The average age of the six patients at the index surgery was 46.2 years (range, 33–61 years). The average time between injury and treatment was 40 days (range, 14–101 days).

Surgery was performed through a deltopectoral approach and splitting of the rotator interval by which the fractured fragments were found and thoroughly released. The dislocated humeral head was reduced. After reduction, the fracture was fixed temporarily with multiple K-pins. A cancellous allograft was then applied to the deficient proximal humerus. Finally, a bent cloverleaf buttress plate was applied to fix the fracture (Fig. 1).

Postoperatively, the involved arm was placed in a sling for 1 month. Pendulum exercise was encouraged immediately after the surgery and passive range of motion exercise was initiated 1 week after surgery (Fig. 2). Assisted active range of motion exercise began 1 month postoperatively. Muscle strengthening exercise was added at the third month after surgery. All patients were routinely

followed up at the clinic with radiological and physical assessment at 2 weeks and 1, 3, 6, and 12 months postsurgery if possible.

3. Results

The average follow-up period for the six patients was 10.4 months (range, 6–24 months). The four patients with a missed diagnosis of fracture dislocation of the shoulder functioned well at the last follow-up. The radiological evaluation for these four patients revealed a solid union. The range of motion of the involved shoulder was lesser by about 10 degrees during flexion and abduction than the noninjured shoulder, but no limitations in daily activity were noted. Pain was not reported in the involved shoulder. All patients were satisfied with the results of the surgery.

Between the two patients who underwent revision surgery for persistent dislocation of the humeral head, the patient with the posterior dislocated head developed an infection in the involved shoulder at 2 months after the surgery. Debridement was performed. However, resorption of the allograft and humeral head occurred in both patients at 4 and 6 months, respectively, after the

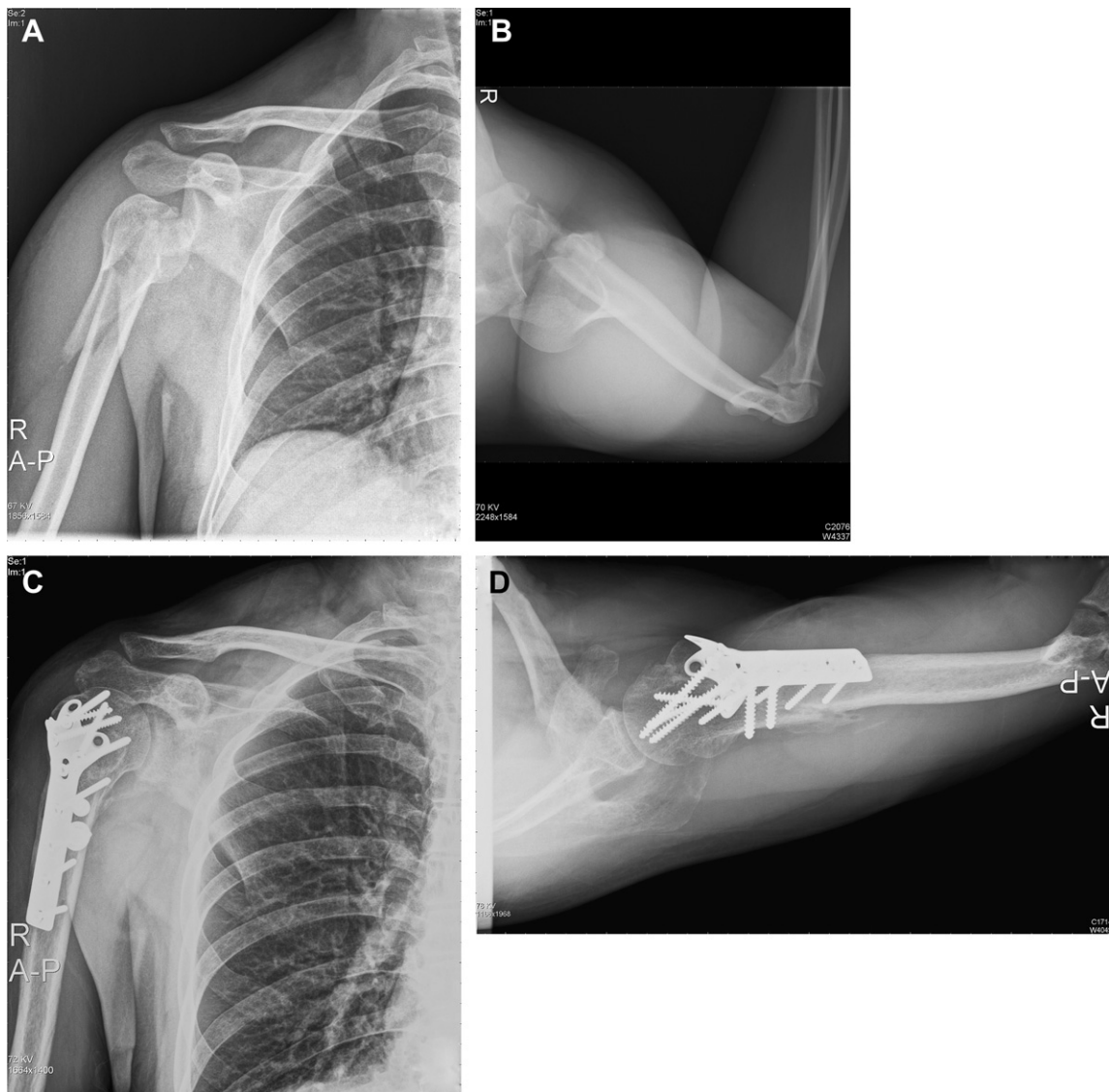


Fig. 1. A 33-year-old man underwent open reduction and internal fixation for a three-part fracture dislocation of the right proximal humerus at 1 month after his injury because of a concomitant injury (A and B). Radiography performed at 1 year after the surgery revealed union of the fracture site (C and D). He retained full range of motion and function of the right shoulder.

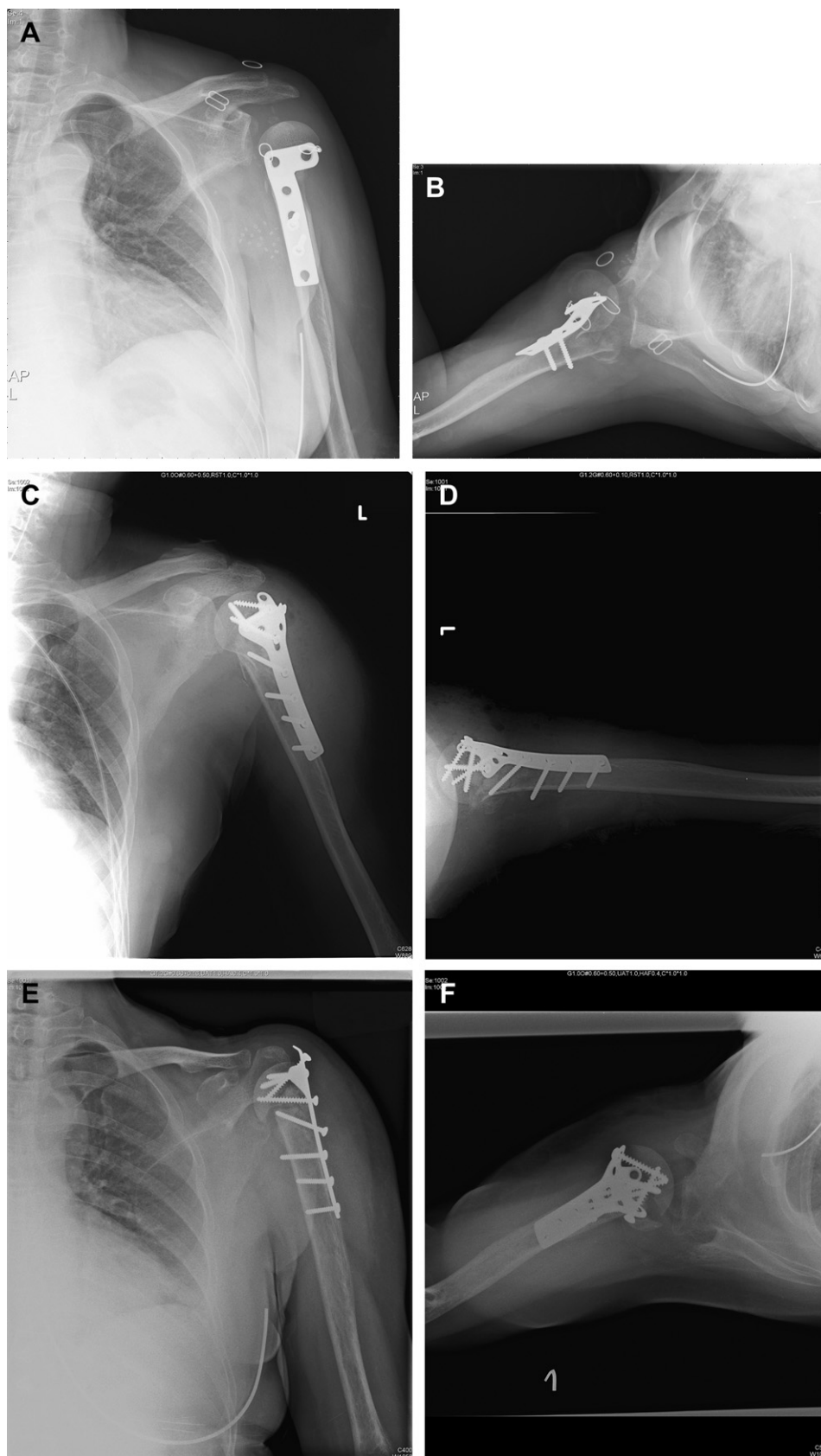


Fig. 2. A 45-year-old woman had persistent anterior dislocation of the humeral head after the first surgery (A and B). After revision surgery, the proximal humerus seemed well reduced and fixed (C and D). However, radiography performed after 6 months revealed nonunion of the fracture site with resorption of the allograft (E and F).

Table 1
Patient data and results.

Age	Sex	Fracture type	Dislocation	Interval (d)	Results
44	M	Three-part	Posterior	14	No limitation in ADL
61	M	Two-part	Anterior	30	No limitation in ADL
33	M	Three-part	Posterior	25	No limitation in ADL
46	M	Two-part	Anterior	40	No limitation in ADL
40	M	Malreduction	Posterior	101	Failure
53	F	Malreduction	Anterior	30	Failure

ADL = activity of daily living.

revision surgery. The patient with the infection was lost to follow-up at 10 months after the index surgery. The other patient underwent shoulder hemiarthroplasty at another hospital at 14 months after the index surgery. Table 1 shows the summary of our six patients.

4. Discussion

Fracture dislocation of the shoulder is an uncommon shoulder injury, and chronic fracture dislocation of the shoulder is even rare. In younger patients, this is often because of high-energy trauma and is associated with multiple injuries. Therefore, this problem may be delayed to be solved until the patients are stable. In older patients, this may be because of falling accidents and is missed because they do not seek for proper treatment and turn out to be chronic. The rate of misdiagnosis for posterior dislocation is much higher than that for anterior dislocation, which may be because of fewer prominent symptoms of posterior dislocation than those of anterior dislocation. Besides of limitation in all directions of shoulder motion, the patients with fixed anterior dislocation have more limitation in internal rotation; and for those with fixed posterior dislocation, more limitation in external rotation is noted.^{7,9–11} In addition, the position of the posteriorly dislocated humeral head is not clearly seen in the anteroposterior radiograph. It is best shown on an axial radiograph; however, axial radiographs are difficult to obtain because of the pain involved in the process.

Although there is a lack of reports of well-controlled studies, a few studies have reported that less favorable functional outcomes are anticipated and risk of complications is high when the fracture dislocation is diagnosed and treated late.^{9,12} In such cases, patients most commonly present with persistent shoulder stiffness and functional incapacity. In most patients, persistent shoulder stiffness tends to be refractory to manipulation and physical therapy regimens alone;¹³ therefore, treatment should be directed at the underlying cause. Generally, the cause of stiffness is assumed to be periarticular fibrosis and capsular contracture, which require thorough surgical release before a repositioning operation is performed over the nonunion/malunion site.

Osteonecrosis of the humeral head after simple dislocation has been reported,¹⁴ and the risk varied according to the degree of fracture displacement and the extent of fracture involvement.^{10,15} However, following anatomical reconstruction, the humeral head may continue to be perfused by intact posteromedial vessels¹¹ or, alternatively, revascularization by creeping substitution may occur.^{16,17} Osteonecrosis may be associated with satisfactory

shoulder function if an anatomic reconstruction was previously achieved.^{18,19}

We have found that for patients with misdiagnosed fracture dislocation of the shoulder, open reduction, internal fixation, and allografting can be performed if the articular cartilage is intact and a satisfactory result can be expected. However, for revision surgery, nonunion and resorption of the fracture site may develop even with allografting and rigid fixation. Poor blood supply after multiple stripping may be the cause of this result. Shoulder hemiarthroplasty is therefore a better treatment for these patients.

In conclusion, complications, such as refractory shoulder stiffness, osteonecrosis, malunion, or nonunion, can occur following proximal humerus fractures. Prompt diagnosis and treatment should be instituted to terminate the ongoing chronicity of the condition and to improve shoulder function. In patients with chronic fracture dislocation of the shoulder who do not undergo operation, a good result can be expected with surgical reconstruction involving osseous realignment and soft tissue management.

References

1. C. Lin, S.G. Krishnan. Orthopaedic Knowledge Update, Chapter 23. Shoulder Trauma. American Academy of Orthopaedics, Rosemont, IL, 2008.
2. S.J. Nho, R.H. Brophy, J.U. Barker, C.N. Cornell, J.D. MacGillivray. Management of proximal humeral fractures based on current literature. *J Bone Joint Surg Am* 89 (2007) 44–58.
3. J.D. Zuckerman, K.J. Kova, F. Cuomo. Fracture of the scapula. *Instr Course Lect* 42 (1993) 271–281.
4. U. Bosch, M. Skutek, R.W. Fremerey, H. Tscherne. Outcome after primary and secondary hemiarthroplasty in elderly patients with fractures of the proximal humerus. *J Shoulder Elbow Surg* 7 (1998) 479–484.
5. M.A. Mighell, G.P. Kolm, C.A. Collinge, M.A. Frankle. Outcomes of hemiarthroplasty for fractures of the proximal humerus. *J Shoulder Elbow Surg* 12 (2003) 569–577.
6. K. Zyto, W.A. Wallace, S.P. Frostick, B.J. Preston. Outcome after hemiarthroplasty for three- and four-part fractures of the proximal humerus. *J Shoulder Elbow Surg* 7 (1998) 85–89.
7. I. Kotela. A case of posterior dislocation of the shoulder with fracture of the humeral neck. *Chir Narzadow Ruchu Orthop Pol* 62 (1997) 105–108 (Polish).
8. K. Takase, A. Watanabe, K. Yamamoto. Chronic posterior dislocation of the glenohumeral joint complicated by a fractured proximal humerus: a case report. *J Orthopaedic Surg* 14 (2006) 204–207.
9. R.J. Hawkins, C.S. Neer 2nd, R.M. Hamta, F.X. Mendoza. Locked posterior dislocation of the shoulder. *J Bone Joint Surg Am* 52 (1970) 1077–1089.
10. R.J. Hawkins. Unrecognized dislocation of the shoulder. *Instr Course Lect* 34 (1985) 258–263.
11. C.K. Lee, H.R. Hansen. Posttraumatic avascular necrosis of the humerus head in displaced proximal humeral fractures. *J Trauma* 21 (1981) 788–791.
12. T.J. Schulz, B. Jacobs, R.L. Patterson Jr. Unrecognized dislocations of the shoulder. *J Trauma* 9 (1969) 1009–1023.
13. F. Postacchini, M. Facchini. The treatment of unreduced dislocation of the shoulder. A review of 12 cases. *Ital J Orthop Traumatol* 13 (1987) 15–26.
14. D.S. Pereira, J.D. Zuckerman. Fracture-dislocations of the shoulder. in: R.F. Warren, E.V. Craig, D.W. Altche (Eds.), *The Unstable Shoulder*. Lippincott-Raven, Philadelphia, PA, 1999.
15. P. Boileau, G. Trojani, G. Walch, S.G. Krishnan, A. Romeo, R. Sinnerton. Shoulder arthroplasty for the treatment of the sequelae of fracture of the proximal humerus. *J Shoulder Elbow Surg* 10 (2001) 299–308.
16. C.H. Brooks, W.J. Revell, F.W. Heatley. Vascularity of the humeral head after proximal humeral fractures. An anatomical cadaver study. *J Bone Joint Surg Br* 75 (1993) 132–136.
17. H. Kofed. Revascularization of the humeral head. A report of two cases of fracture-dislocation of the shoulder. *Clin Orthop* 179 (1983) 175–178.
18. C. Gerber, O. Hersche, C. Berberat. The clinical relevance of posttraumatic avascular necrosis of the humeral head. *J Shoulder Elbow Surg* 7 (1998) 586–590.
19. A.J. Wiggins, W. Roolker, T.W. Patt, E.L.F.B. Raaymakers, R.K. Marti. Open reduction and internal fixation for three and four-part fractures of the proximal part of the humerus. *J Bone Joint Surg Am* 84 (2002) 1919–1925.